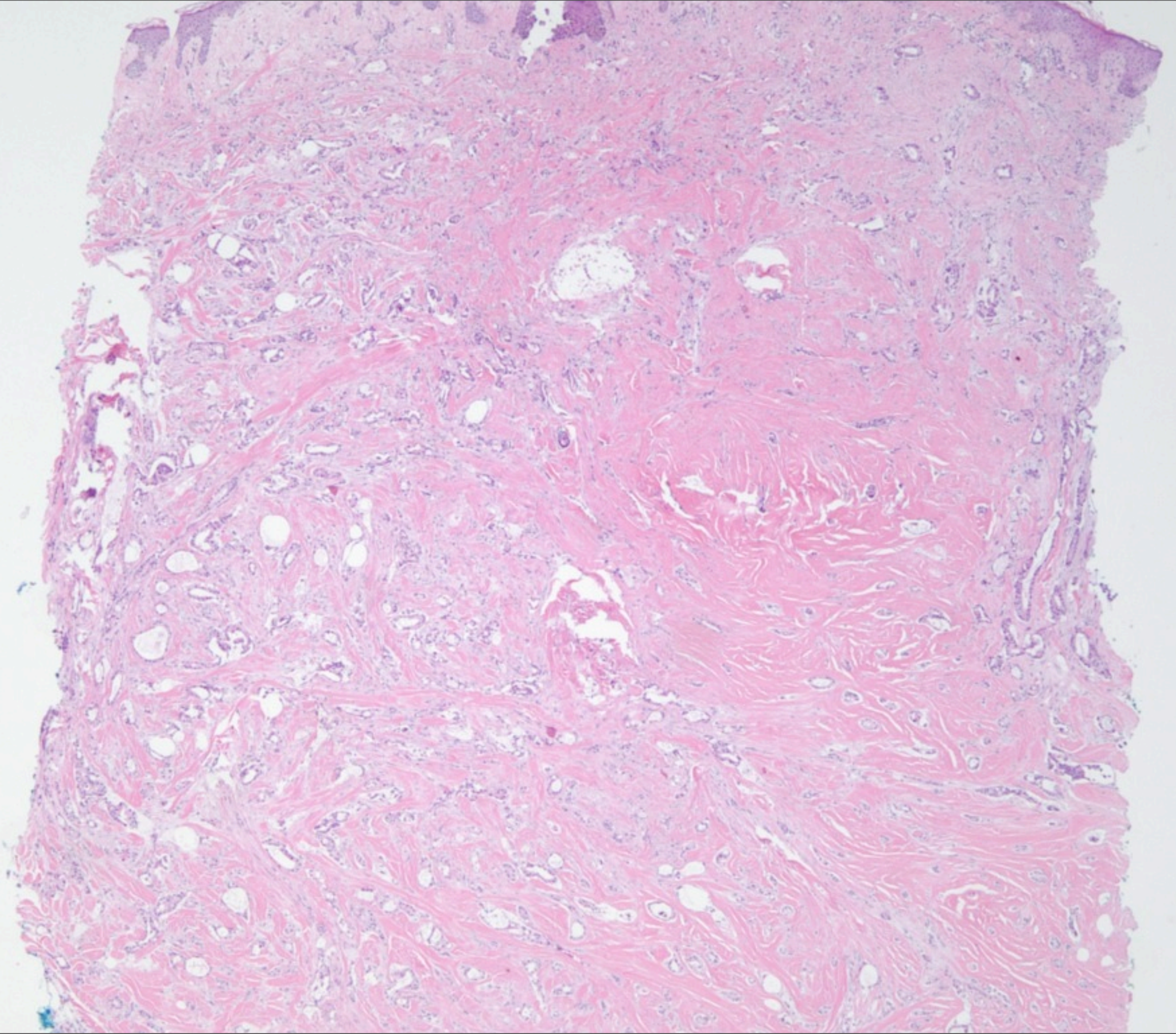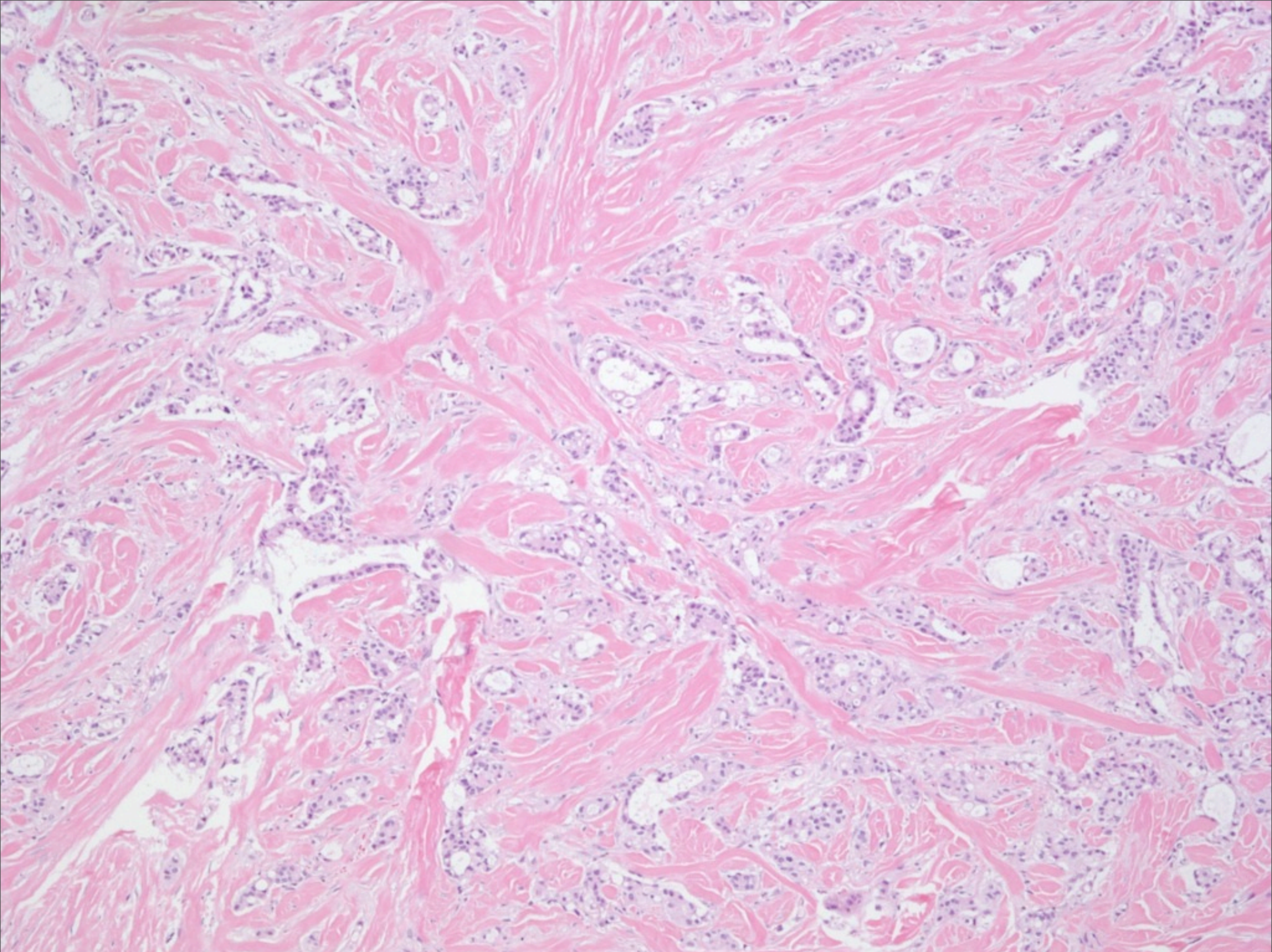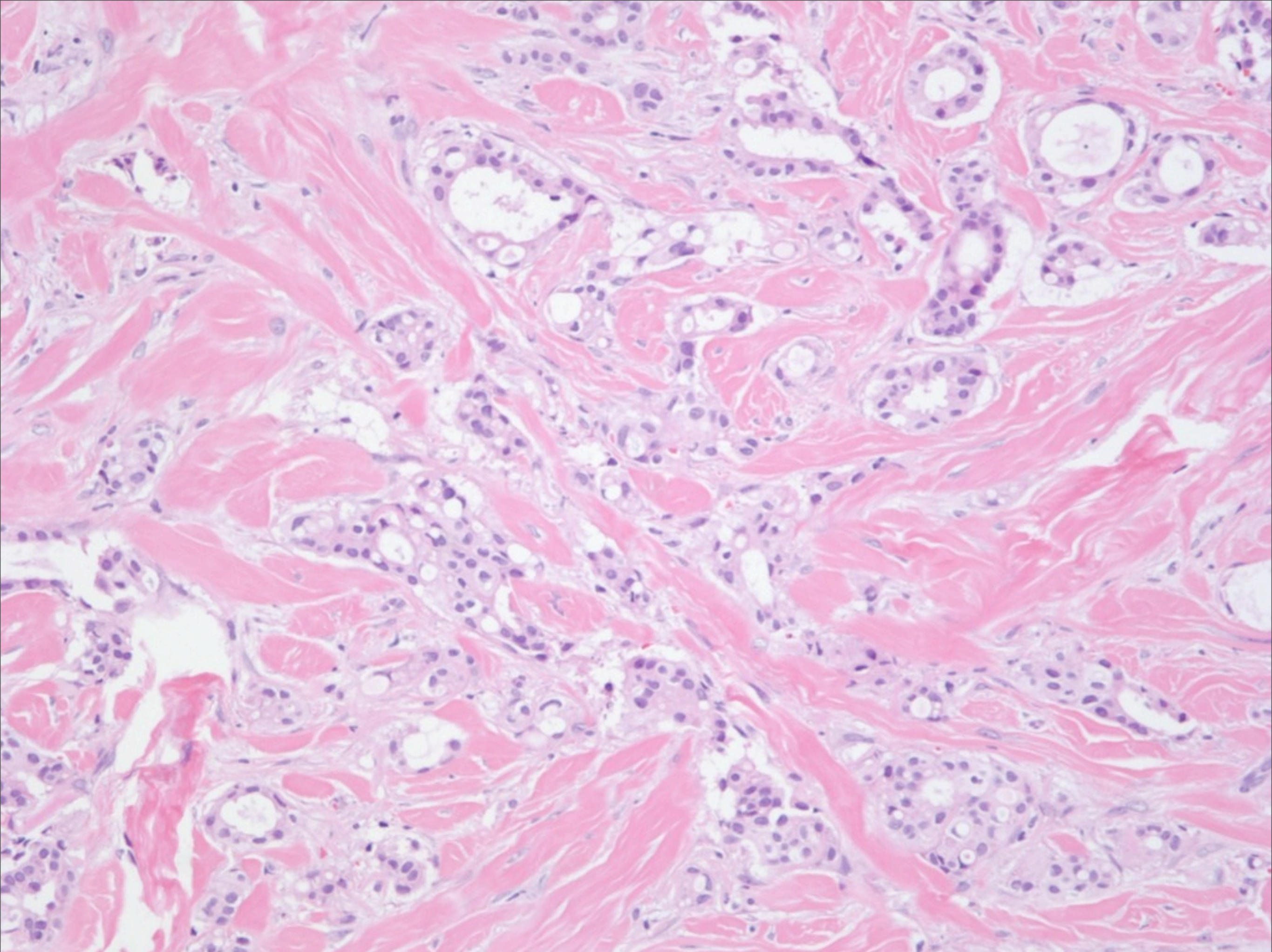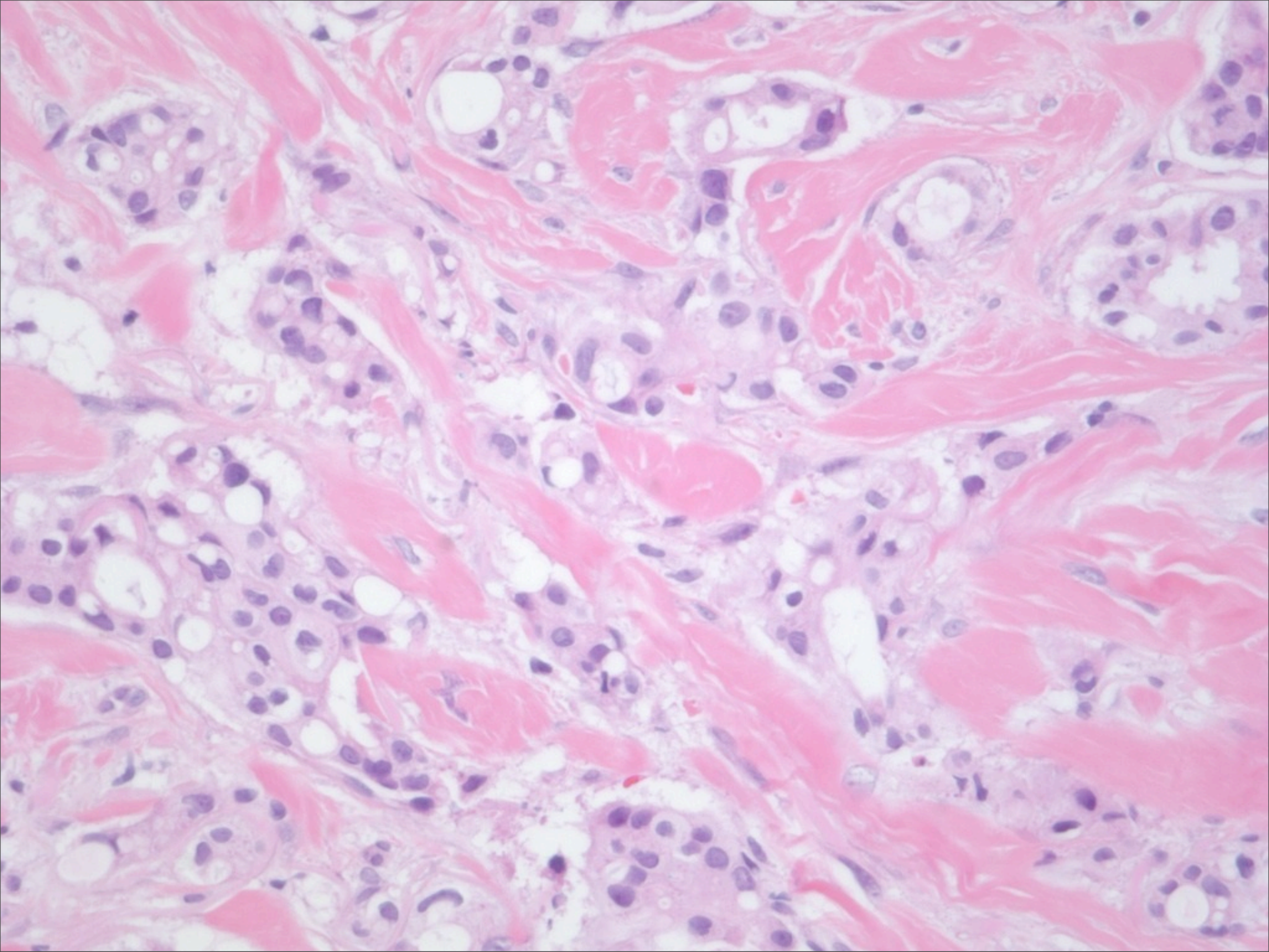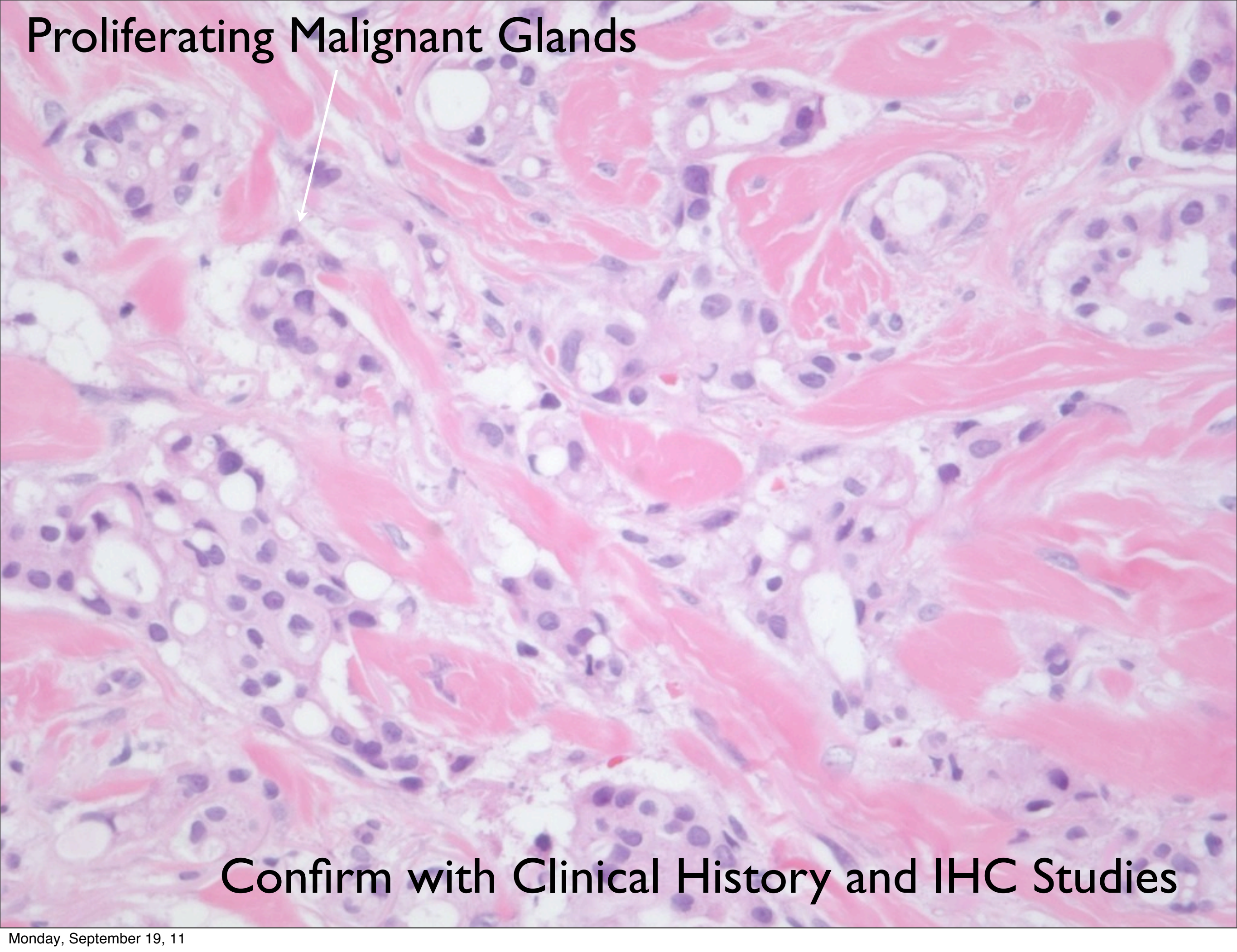


Metastatic Adenocarcinoma, Consistent with Breast Primary

Proliferating Malignant Glands



Confirm with Clinical History and IHC Studies